

# Botulinum Toxin in Men: Review of Relevant Anatomy and Clinical Trial Data

TERRENCE C. KEANEY, MD, AND TINA S. ALSTER, MD\*

---

**BACKGROUND** Botulinum toxin is widely used for facial aesthetics, and its use in men continues to increase.

**OBJECTIVE** To provide a review of pertinent male anatomic features and updated clinical information on the use of botulinum toxin in men.

**METHODS** A Medline search was performed for publications on sex differences in facial anatomy and on clinical studies examining the role of sex in botulinum toxin treatment.

**RESULTS** There are substantial facial anatomic differences between the sexes, with men having increased cranial size, unique cranial shape, greater skeletal muscle mass, higher density of facial blood vessels, and more-severe facial rhytides. A review of sex and botulinum toxin treatment identified 17 clinical studies with 5,646 total participants, of whom 629 (11.1%) were male. Only two studies accounted for sex in study design or subgroup analysis. Both studies found abobotulinumtoxinA to be less effective in men. An additional study examining onabotulinumtoxinA dosing in men found that higher doses than typically used in women were more efficacious. There were not more adverse events in male participants in any study.

**CONCLUSION** Despite sex differences in facial anatomy, the use of botulinum toxin in men is inadequately studied with regard to dosing, efficacy, and safety.

*The authors have indicated no significant interest with commercial supporters.*

---

There are three Food and Drug Administration (FDA)-approved botulinum toxin formulations currently available in the United States for cosmetic use: onabotulinumtoxinA (Botox Cosmetic, Allergan, Inc., Irvine, CA), abobotulinumtoxinA (Dysport, Valeant Pharmaceuticals International, Montreal, Canada), and incobotulinumtoxinA (Xeomin, Merz Pharmaceuticals, Frankfurt, Germany). All of the agents are used for the temporary improvement of moderate to severe glabellar lines. Treatment with botulinum toxin was the single most common cosmetic procedure in 2011, accounting for nearly 41% of all cosmetic procedures performed in the United States. Although it was the most common procedure performed in

both sexes, men represented only 6% of patients, but over the last several years, this conservative trend in men seems to be changing. The number of men seeking botulinum toxin injections has increased by 8% since 2010 and 268% since 2000—totaling 363,018 injections in 2011.<sup>1</sup> The increase in men undergoing botulinum toxin injections is multifactorial. A desire to be more competitive and youthful in the workforce, the growing social acceptability of cosmetic procedures, and greater awareness of the safety and efficacy of botulinum toxin may all be contributing to the increase in male patients. In addition, botulinum toxin offers immediate results without mandatory post-treatment recovery, allowing men to return to work immediately.

*\*Both authors are affiliated with the Washington Institute of Dermatologic Laser Surgery, Washington, District of Columbia*

© 2013 by the American Society for Dermatologic Surgery, Inc. • Published by Wiley Periodicals, Inc. • ISSN: 1076-0512 • Dermatol Surg 2013;39:1434–1443 • DOI: 10.1111/dsu.12302

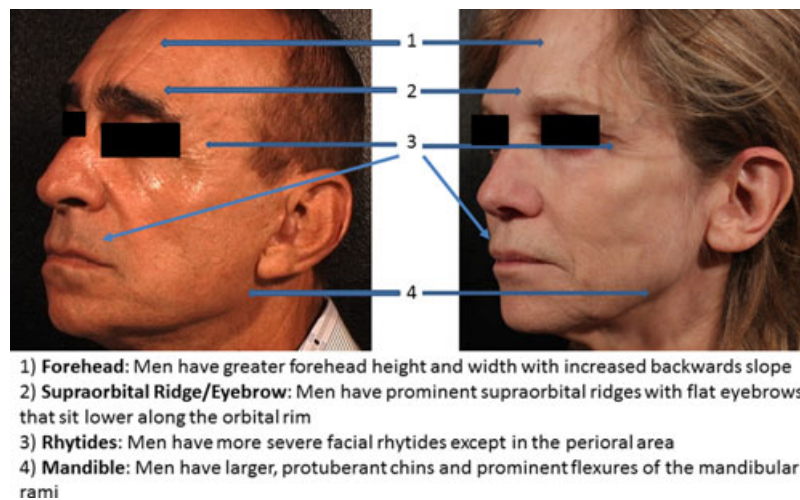
Achieving the desired outcome with botulinum toxin treatment in men requires proper dosing, an understanding of the safety profile, appropriate patient selection, and accurate placement of the neurotoxin. Clinical data can guide proper dosing and safety, and patient selection and accurate placement of botulinum toxin require a thorough understanding of male facial anatomy. This article will guide physicians on the use of botulinum toxin in men by reviewing the scientific literature on male facial anatomy and clinical data regarding its use in men.

### Male Facial Anatomy

Sexual dimorphism refers to the phenotypic differences between sexes of the same species. In humans, these differences are wide ranging and are reflected in the differences in external genitalia, greater musculature, and larger skeletal anatomy in men than women.<sup>2</sup> Sexual dimorphism in facial anatomy (Figure 1) is well documented, yet few differences are discussed in facial aesthetic literature. When using botulinum toxin, the entire facial form, including the skeletal structure, the musculature, the vasculature, and the skin, is important to evaluate. Although facial musculature is typically the focus when injecting botulinum toxin, there are other

sexually dimorphic anatomic features that are important to evaluate.

Differences in the facial skeleton contribute to sexually dimorphic soft tissues. The size of the female skull is on average four-fifths the size of the male skull,<sup>3</sup> but there are also differences in skeletal landmarks and overall cranial shape. Men have prominent supraorbital ridges<sup>4</sup> that provide an anatomical landmark for the eyebrow position. In women, the eyebrow tends to lie just above the supraorbital ridge and has an arch peaking in the lateral third.<sup>5</sup> In men, the eyebrow is flatter in contour and sits lower along the orbital rim than in women.<sup>6</sup> Because the medial supraorbital ridge blends into the glabella, men have a greater glabellar projection than women.<sup>7</sup> Glabellar sex differences are so pronounced that older methods<sup>8</sup> of sex determination of skeletons relied on the width and projection at the glabella. The forehead begins at the supraorbital ridge and slopes backward to the hairline. Forehead height and width are greater in men than in women, with a greater backward slope.<sup>9</sup> The forehead contour in women is higher, smoother, and rounded to the point of forward protrusion.<sup>9</sup> Although the orbital height is smaller and more oval in women, the female orbit is proportionally larger in relation to the size of the skull.<sup>10</sup> Men also have a



**Figure 1.** Sex differences in facial anatomy.

wider and larger chin, with forward prominence.<sup>11</sup> Prominent flexure of the mandibular ramus is typical of the male jaw and is commonly used in skeletal sex determination.<sup>12</sup> The skeletal differences between the sexes contribute to unique anatomic features of the aging male face.

Given that botulinum toxin targets facial muscles, sex differences in facial musculature are critical to identify when using botulinum toxin in men. In a study examining skeletal muscle mass in 468 men and women, men had a significantly greater amount of skeletal muscle than women (33 vs 21 kg).<sup>13</sup> Although no study has examined differences in the muscle mass of facial mimetic muscles, there are sex differences in facial muscle movement, with men having greater facial movement after adjusting for differences in facial size.<sup>14</sup> Men also have been shown to have a greater upward vertical movement capacity in facial expressions such as smiling and puckering their lips.<sup>15</sup> Because facial movement contributes to rhytid formation, it is no surprise that there are also sex differences in the severity and distribution of facial rhytides. A study of 173 Japanese men and women documented that men tend to have more-severe facial rhytides than women.<sup>16</sup> The perioral area is the only area where women develop deeper rhytides, which is thought to be due to the significantly smaller pilosebaceous units in the oral region.<sup>17</sup> Other age-related changes exhibit sexual dimorphism. Aging causes a downward shift of the lower eyelid that is significantly more severe in older men.<sup>18,19</sup> The subcutaneous adipose layer is thinner in men regardless of age,<sup>20</sup> which may also contribute to the greater severity of male rhytides.

Botulinum toxin injection carries the risk of bruising due to disruption of the blood vessels in the dermal vascular plexus. The male facial vascular pattern has a greater density of blood vessels.<sup>21</sup> A Doppler flow perfusion study of male and female facial skin documented greater perfusion in men, principally because of the larger number of microvessels present.<sup>22</sup> The greater vascularity of

the male face may be attributed to the presence of coarse facial hair. A dense plexus of arteries supports the hair follicles, and the vascular supply to a given hair follicle depends on the size of the follicle. Follicles with a large diameter tend to have more capillaries that pass through the dermal papilla.<sup>23</sup> The greater vascularity of male skin may contribute to the greater incidence of postoperative bleeding complications in men undergoing facial plastic surgery.<sup>24</sup>

### Botulinum Toxin in Men

A Medline review was conducted to identify pivotal clinical studies<sup>25-39</sup> involving botulinum toxin treatment of the upper face. Only clinical studies with male and female participants were included. Seventeen studies were identified with 5,646 study participants (Table 1). A total of 629 men were enrolled, representing 11.1% of all study participants. Male participation was higher in the abobotulinumtoxinA clinical studies (12.9%) than in the onabotulinumtoxinA (10.4%) and incobotulinumtoxinA (11%) studies. Only two of the clinical studies accounted for gender by either adjusting the dosing or performing subgroup analyses. The two studies were conducted with abobotulinumtoxinA.

A prospective, randomized, double-blind, placebo-controlled, parallel-group, phase 3 study performed subgroup analysis of the efficacy and safety of abobotulinumtoxinA in the treatment of glabellar lines.<sup>34</sup> Of the 158 subjects randomized in a 2:1 ratio to receive a single 50-unit injection of abobotulinumtoxinA or placebo, 23 (15%) were men. Women in the abobotulinumtoxinA group were more likely to respond, defined as a significant reduction in Glabellar Line Scale Score (investigator and subject assessments of 93% and 83%, respectively) than were men (67% and 33%, respectively). No sex difference in treatment-emergent adverse events was noted. The investigators concluded that treatment of the male glabella requires an abobotulinumtoxinA dose greater than 50 U.

TABLE 1. Pivotal Clinical Studies Involving Botulinum Toxin Treatment of the Upper Face

Location	Study Authors	Year	Study Design	Botulinum Toxin	Male Patients	Female Patients	Male% of Sample Size	Dose	Gender Dosing Adjustment	Gender Subgroup Analysis
Glabella	Carruthers, et al. <sup>25</sup>	2002	Multicenter, double-blind, randomized, placebo-controlled study	OnabotulinumtoxinA	44	220	16.7%	20U	No	No
Crow's Feet	Lowe NJ, et al. <sup>26</sup>	2002	Single Center, double-blind, randomized, placebo controlled comparison of 3 doses of	OnabotulinumtoxinA	9	51	15.0%	6, 12, or 18U (per side)	No	No
Crow's Feet	Lowe NJ, et al. <sup>27</sup>	2005	Multicenter, Double-blind, randomized, placebo-controlled, dose-response study	OnabotulinumtoxinA	18	144	11.1%	3, 6, 12, 18U (per side)	No	No
Glabella	Ascher B, et al. <sup>28</sup>	2004	Multicenter, double-blind, randomized, placebo controlled, dose-ranging study	OnabotulinumtoxinA	5	114	4.2%	25, 50, 75U	No	No
Glabella	Harii K, et al. <sup>29</sup>	2008	Double-blind, randomized, placebo-controlled, dose-ranging study	OnabotulinumtoxinA	13	122	9.6%	10, 20U	No	No
Glabella	Kawashima M, et al. <sup>30</sup>	2009	Open-label, randomized, dose ranging study	OnabotulinumtoxinA	18	345	5.0%	10, 20U	No	No

TABLE 1. Continued

Location	Study Authors	Year	Study Design	Botulinum Toxin	Male Patients	Female Patients	Male% of Sample Size	Dose	Gender Dosing Adjustment	Gender Subgroup Analysis
Glabella	Wu Y, et al. <sup>28</sup>	2010	Prospective, double-blind, randomized, placebo-controlled study	OnabotulinumtoxinA	32	195	14.1%	10, 20U	No	No
Glabella	Ascher B, et al. <sup>31</sup>	2004	Multicenter, randomized, double-blind, placebo-controlled, dose-ranging study	AbobotulinumtoxinA	5	114	4.2%	25, 50, 75U	No	No
Glabella, Brow	Rzany B, et al. <sup>32</sup>	2006	Multicenter, randomized, double-blind, placebo-controlled, dose-ranging study	AbobotulinumtoxinA	22	198	10.0%	30 or 50U	No	No
Glabella	Monheit G, et al. <sup>33</sup>	2007	Multicenter, randomized, double-blind, placebo-controlled, dose-ranging study	AbobotulinumtoxinA	60	313	16.1%	25, 50, 75U	No	No
Lateral Canthi	Ascher B, et al. <sup>34</sup>	2009	Multicenter, randomized, double-blind, placebo-controlled, dose-ranging study	AbobotulinumtoxinA	26	192	11.9%	15, 30, 45U (per side)	No	No
Glabella	Brandt F, et al. <sup>35</sup>	2009	Randomized, placebo-controlled study	AbobotulinumtoxinA	23	135	15.0%	50U	No	Yes
Glabella	Kane MA, et al. <sup>36</sup>	2009	Multicenter, randomized, double-blind, placebo-controlled, dose-ranging study	AbobotulinumtoxinA	97	719	11.8%	Females: 50, 60, 70U Males: 60, 70, 80U	Yes	Yes

TABLE 1. Continued

Location	Study Authors	Year	Study Design	Botulinum Toxin	Male Patients	Female Patients	Male% of Sample Size	Dose	Gender Dosing Adjustment	Gender Subgroup Analysis
Glabella	Rubin MG, et al. <sup>37</sup>	2009	Multicenter, randomized, double-blind, placebo-controlled, dose-ranging study	AbobotulinumtoxinA	42	269	14.0%	50U	No	No
Glabella	Moy R, et al. <sup>38</sup>	2009	Phase 3, open label, multicenter study	AbobotulinumtoxinA	116	1084	9.7%	50U	No	No
Glabella	Imhof M, et al. <sup>38</sup>	2011	Prospective, open-label, multicenter study	IncobotulinumtoxinA	5	100	4.8%	20U	No	No
Glabella	Rzany B, et al. <sup>39</sup>	2013	Prospective, open-label, multicenter study	IncobotulinumtoxinA	94	702	11.8%	20U	No	No
				OnabotulinumtoxinA	139	1191	10.4%			
				AbobotulinumtoxinA	391	3024	12.9%			
				IncobotulinumtoxinA	99	802	11.0%			
				Total	629	5017	11.1%			

The only multicenter, randomized, double-blinded, placebo-controlled study that adjusted botulinum toxin dosing for the different sexes was published in 2009.<sup>35</sup> Enrolled patients were randomized to one treatment of placebo or variably dosed abobotulinumtoxinA based on glabellar muscle mass and patient sex; 97 men (11.8% of participants) were randomized to receive placebo or 60, 70, or 80 U of abobotulinumtoxinA in the glabellar complex depending on physician assessment of muscle mass. Women were randomized to receive placebo or 50, 60, or 70–10 U less than men for the same muscle mass rating. Men had a statistically significant lower Glabellar Line Severity (GLS) score with abobotulinumtoxinA treatment than with placebo. Of the 62 men randomized to the abobotulinumtoxinA treatment arm, 40 (65%) were deemed responders. In comparison, 415 of the 475 of the female participants (87%) in the abobotulinumtoxinA treatment arm were responders. Additional subgroup analysis revealed that independent of sex, participants with large muscle mass and high baseline GLS score had lower response rates; 65% of the men were assessed as having large muscle mass, and 90% had a high baseline GLS score.<sup>40</sup> In contrast, 38% of women were assigned to the large muscle mass group, and 55% had a high baseline GLS score. The study's results suggest that men are less responsive to the doses used and have larger muscle mass and more-severe rhytides than women. There were no more adverse events in the men and no men reported an ocular side effect. The investigators recommended using larger doses of abobotulinumtoxinA in men.

The Medline search was expanded to identify any study that specifically examined the use of botulinum toxin in men. Only one study examined the dose–response relationship in men using varying doses of onabotulinumtoxinA.<sup>41</sup> Eighty men were randomized to receive 20, 40, 60, or 80 U of onabotulinumtoxinA in the glabellar complex. Glabellar rhytides were evaluated using the Facial Wrinkle Scale. Higher doses were more effective and tended to provide more durable responses on all

measures than the 20-U dose. Men also reported a dose-dependent relationship between their ability to frown; better global assessment; and greater feelings of attractiveness, self-confidence, and satisfaction. No association between dose and occurrence of adverse events was detected. The investigators concluded that 20 U was an inadequate dose in the glabellar complex and recommended starting men at a dose approximately twice the typical dose used in women (60–80 U).

## Discussion

A review of the scientific literature regarding facial anatomy documents substantial anatomic differences between the sexes. The male skull is not only larger, but also has a different shape. Men tend to have a large forehead with prominent supraorbital ridges, wide glabella, square orbit, and a prominent protruding mandible. Men have greater skeletal muscle mass, including facial mimetic muscles. Men have a highly vascularized face and more-severe facial rhytides except in the perioral area. These anatomic differences should be considered in any facial aesthetic study whether through subgroup analyses or sex-specific study design.

Despite the fact that it has been more than 10 years since the FDA approved the cosmetic use of botulinum toxin, only three studies have examined the role of sex in botulinum toxin dosing, efficacy, or safety. The pivotal clinical studies enrolled significantly fewer men than women, although the overall percentage (11.1%) of male participants in the reviewed clinical studies exceeds the American Society of Plastic Surgeons survey data regarding number of men undergoing botulinum toxin injections in 2011 (6%). Only two studies accounted for sex in study design or subgroup analysis. Both studies found abobotulinumtoxinA less effective in men than women. Only one of the two clinical studies adjusted the dose for men, with men receiving 10 U more of abobotulinumtoxinA than women for the same muscle mass rating. Despite the higher dose, men were less likely to respond to

treatment. The investigators in both studies recommended higher doses in men. Dosing in men was specifically examined in an onabotulinumtoxinA study. Results indicated that higher doses were more efficacious, and the investigators recommended doubling the dose commonly used in women. There were no more adverse events in men in any of the reviewed studies.

The similar safety profile of botulinum toxin in men and women is important to note considering the anatomic differences between the sexes. Because of the greater density of vessels in male facial skin and low eyebrow position along the orbital rim, there are theoretical risks of greater bruising and eyebrow ptosis in men. Those side effects were not observed in the reviewed clinical trials. Because it is postulated that the greater facial vascularity is due to vascular plexus associated with terminal hairs in the beard area, botulinum toxin injections in the upper face would avoid the blood vessels associated with terminal hairs. A greater risk of bruising in men may be more problematic with the use of dermal fillers in the lower face. The absence of eyebrow ptosis in the clinical studies may be the result of inadequate dosing in men. The frontalis muscle of men may require higher doses to cause a clinically significant difference in eyebrow ptosis.

The results of this review raise broader questions regarding the treatment of the male face. Is the sex difference in efficacy truly a function of inadequate dosing, or are there are other factors such as physiologic differences in receptor binding or diffusion? What is the best way to dose male botulinum toxin patients? Establishing the correct botulinum toxin dose requires customized treatment to the patient's face, yet one cannot ignore that men have larger facial muscles. How good are injectors at assessing male muscle mass and, thus, proper dosing, seeing as 94% of botulinum toxin injections are performed in women? The standardized doses used in clinical trials may not be suitable for all patients but provide guidance to practicing physicians. The doses used in the clinical trials were not

sufficient in men even when variable dosing was incorporated into the study design. Should all men be dosed at approximately twice the dose of women, as Carruthers<sup>41</sup> suggests? What dose should be used in other muscle groups of the male face? The sensitivity of muscles to botulinum toxin can differ markedly, and the ideal dose for the glabella may not be transposed to another muscle group. All of these questions offer opportunity for future study.

Men may represent a small proportion of botulinum toxin patients, but they are a growing segment of cosmetic practices. Greater attention to male cosmetic patients, academically and commercially, will not only lead to better treatment, but may also attract more men for botulinum toxin treatment. In addition, men are an underserved patient population that could benefit from botulinum toxin given their large facial muscles and more-severe facial rhytides. As the number of men seeking treatment of the aging face increases, it behooves the dermatology community to expand our understanding of the underlying biology of the aging male face and its appropriate treatment with botulinum toxin. Nonetheless, when evaluating a botulinum toxin patient, it is vital to account for the sex of the patient.

## References

1. American Society for Plastic Surgery 2011 statistics. Available from: <http://www.plasticsurgery.org/News-and-Resources/2011-Statistics-.html> Accessed November 5, 2012.
2. Gallagher D, Heymsfield SB. Muscle distribution: variations with body weight, gender, and age. *Appl Radiat Isot* 1998;49:733-4.
3. Krogman WM. Sexing skeletal remains. In: Krogman WM, editor. *The human skeleton in forensic medicine*. Springfield, IL: Charles C. Thomas; 1973. pp. 112.
4. Garvin HM, Ruff CB. Sexual dimorphism in skeletal browridge and chin morphologies determined using a new quantitative method. *Am J Phys Anthropol* 2012;147:661-70.
5. Gunter JP, Antrobus SD. Aesthetic analysis of the eyebrows. *Plast Reconstr Surg* 1997;99:1808-16.
6. Goldstein SM, Katowitz JA. The male eyebrow: a topographic anatomic analysis. *Ophthal Plast Reconstr Surg* 2005;21:285-91.



7. Russell MD. The supraorbital torus: a most remarkable peculiarity. *Curr Anthropol* 1985;26:337–60.
8. Ferembach D, Schwidetzky I, Stloukal M. Recommendations for age and sex diagnoses of skeletons. *J Hum Evol* 1980;9:517–49.
9. Whitaker LA, Morales L Jr, Farkas LG. Aesthetic surgery of the supraorbital ridge and forehead structures. *Plast Reconstr Surg* 1986;78:23.
10. Pretorius E, Steyn M, Scholtz Y. Investigation into the usability of geometric morphometric analysis in assessment of sexual dimorphism. *Am J Phys Anthropol* 2006;129:64–70.
11. Thayer ZM, Dobson SD. Sexual dimorphism in chin shape: implications for adaptive hypotheses. *Am J Phys Anthropol* 2010;143:417–25.
12. Donnelly S, Hens SM, Rogers NL, Schneider KL. A blind test of mandibular ramus flexure as a morphological indicator of sexual dimorphism in the human skeleton. *Am J Phys Anthropol* 1998;107:363–6.
13. Janssen I, Hemsfield S, Wang Z, Ross R. Skeletal muscle mass and distribution in 468 men and women aged 18–88 years. *J Appl Physiol* 2000;89:81–8.
14. Weeden JC, Trotman CA, Faraway JJ. Three dimensional analysis of facial movement in normal adults: influence of sex and facial shape. *Angle Orthod* 2001;71:132–40.
15. Houstis O, Kiliaridis S. Gender and age differences in facial expressions. *Eur J Orthod* 2009;31:459–66.
16. Tsukahara K, Hotta M, Osanai O, Kawada H, et al. Gender-dependent differences in degree of facial wrinkles. *Skin Res Technol* 2013;19(1):65–71.
17. Paes EC, Teepen HJ, Koop WA, Kon M. Perioral wrinkles: histologic differences between men and women. *Aesthet Surg J* 2009;29:467–72.
18. van den Bosch WA, Leenders I, Mulder P. Topographic anatomy of the eyelids, and the effects of sex and age. *Br J Ophthalmol* 1999;83:347–52.
19. Ezure T, Yagi E, Kunizawa N, Hirao T, et al. Comparison of sagging at the cheek and lower eyelid between male and female faces. *Skin Res Technol* 2011;17:510–5.
20. Sjoström L, Smith U, Krotkiewski M, Björntorp P. Cellularity in different regions of adipose tissue in young men and women. *Metabolism* 1972;21:1143–53.
21. Moretti G, Ellis RA, Mescon H. Vascular patterns in the skin of the face. *J Invest Dermatol* 1959;33:103–12.
22. Mayrovitz HN, Regan MB. Gender differences in facial skin blood perfusion during basal and heated conditions determined by laser Doppler flowmetry. *Microvasc Res* 1993;45:211–8.
23. Montagna W, Ellis RA. Histology and cytochemistry of human skin. XIII. The blood supply of the hair follicle. *J Natl Cancer Inst* 1957;19:451–63.
24. Baker DC, Stefani WA, Chiu ES. Reducing the incidence of hematoma requiring surgical evacuation following male rhytidectomy: a 30-year review of 985 cases. *Plast Reconstr Surg* 2005;116:1973–85.
25. Carruthers JA, Lowe NJ, Menter MA, Gibson J, et al. A multicenter, double-blind, randomized, placebo-controlled study of the efficacy and safety of botulinum toxin type A in the treatment of glabellar lines. *J Am Acad Dermatol* 2002;46:840–9.
26. Lowe NJ, Lask G, Yamauchi P, Moore D. Bilateral, double-blind, randomized comparison of 3 doses of botulinum toxin type A and placebo in patients with crow's feet. *J Am Acad Dermatol* 2002;47:834–40.
27. Lowe NJ, Ascher B, Heckmann M, Kumar C, et al. Double-blind, randomized, placebo-controlled, dose-response study of the safety and efficacy of botulinum toxin type A in subjects with crow's feet. *Dermatol Surg* 2005;31:257–62.
28. Ascher B, Zakine B, Kestemont P, Baspeyras M, et al. A multicenter, randomized, double-blind, placebo-controlled study of efficacy and safety of 3 doses of botulinum toxin A in the treatment of glabellar lines. *J Am Acad Dermatol* 2004;51:223–33.
29. Harii K, Kawashima M. A double-blind, randomized, placebo-controlled, two-dose comparative study of botulinum toxin type A for treating glabellar lines in Japanese subjects. *Aesthetic Plast Surg* 2008;32:724–30.
30. Kawashima M, Harii K. An open-label, randomized, 64-week study repeating 10- and 20-U doses of botulinum toxin type A for treatment of glabellar lines in Japanese subjects. *Int J Dermatol* 2009;48:768–76.
31. Rzany B, Ascher B, Fratila A, Monheit GD, et al. Efficacy and safety of 3- and 5-injection patterns (30 and 50 U) of botulinum toxin A (Dysport) for the treatment of wrinkles in the glabella and the central forehead region. *Arch Dermatol* 2006;142:320–6.
32. Monheit G, Carruthers A, Brandt F, Rand R. A randomized, double-blind, placebo-controlled study of botulinum toxin type A for the treatment of glabellar lines: determination of optimal dose. *Dermatol Surg* 2007;33(1 Spec No.):S51–9.
33. Ascher B, Rzany BJ, Grover R. Efficacy and safety of botulinum toxin type A in the treatment of lateral crow's feet: double-blind, placebo-controlled, dose-ranging study. *Dermatol Surg* 2009;35:1478–86.
34. Brandt F, Swanson N, Baumann L, Huber B. Randomized, placebo-controlled study of a new botulinum toxin type a for treatment of glabellar lines: efficacy and safety. *Dermatol Surg* 2009;35:1893–901.
35. Kane MAC, Brandt F, Rohrich RJ, Narins RS, et al. Evaluation of variable-dose treatment with a new US botulinum toxin type A (Dysport) for correction of moderate to severe glabellar lines: results from a phase 3, randomized, double-blind, placebo-controlled study. *Plast Reconstr Surg* 2009;124:1619–29.
36. Rubin MG, Dover JS, Glogau RG, Goldberg DJ, et al. The efficacy and safety of a new U.S. botulinum toxin type A in the retreatment of glabellar lines following open-label treatment. *J Drugs Dermatol* 2009;8:439–44.
37. Moy R, Maas C, Monheit G, Huber MB. Long-term safety and efficacy of a new botulinum toxin type A in treating glabellar lines. *Arch Facial Plast Surg* 2009;11:77–83.
38. Imhof M, Kühne U. A phase III study of incobotulinumtoxinA in the treatment of glabellar frown lines. *J Clin Aesthet Dermatol* 2011;4:28–34.

39. Rzany B, Flynn TC, Schlöbe A, Heinz M, et al. Long-term results for incobotulinumtoxinA in the treatment of Glabellar Frown lines. *Dermatol Surg* 2013;39(1 Pt 1):95–103.
40. Baumann L, Brandt FS, Kane MA, Donofrio LM. An analysis of efficacy data from four phase III studies of botulinum neurotoxin type A-ABO for the treatment of glabellar lines. *Aesthet Surg J* 2009;29(Suppl 6):S57–65.
41. Carruthers A, Carruthers J. Prospective, double-blind, randomized, parallel-group, dose-ranging study of botulinum toxin type A in men with glabellar rhytids. *Dermatol Surg* 2005;31:1297–303.

---

Address correspondence and reprint requests to: Tina Alster, MD, Washington Institute of Dermatologic Laser Surgery, 1430 K Street, NW Suite 200, Washington, District of Columbia 20005, or e-mail: talter@skinlaser.com